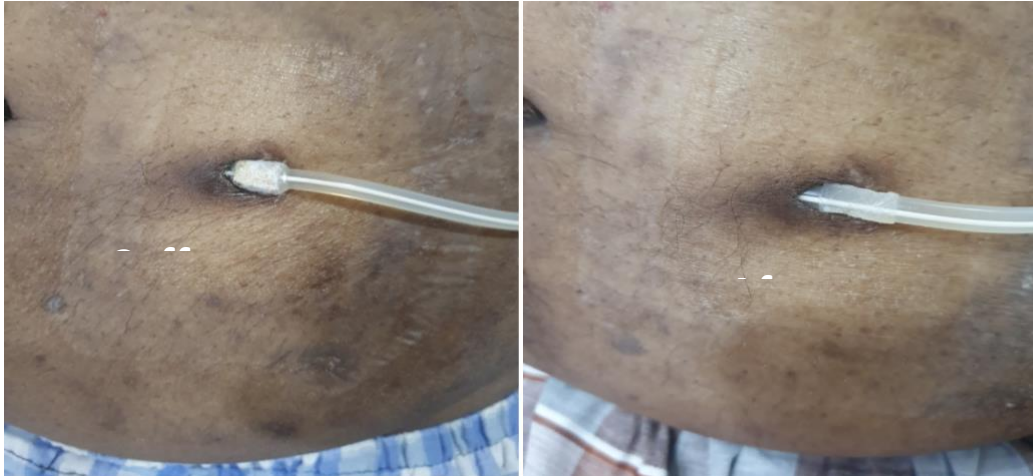


Image in Nephrology



Peritoneal dialysis catheter superficial cuff extrusion with time. Patient was on Peritoneal dialysis for one year. The superficial cuff was removed with the help of gentle repeated pulls on the Dacron fibers. Shaving the Dacron cuff with the help of a specific shaver can be an alternative also. If left alone, may cause trauma and repeated exit site infections.

Reference:

Koratala A, Michael Kazory A,. Catheter Cuff Extrusion Following Exit-Site Infection in an Immunosuppressed Patient: One Case and Two Lessons. *Blood Purif* 2018;45;343 - 344. <https://doi.org/10.1159/000487124>

Submitted by:

Minahil Ismail
Byonyks Medical Device company
Lahore, Pakistan & Chicago, USA
Email: minahil.ismaeel@byonyks.com