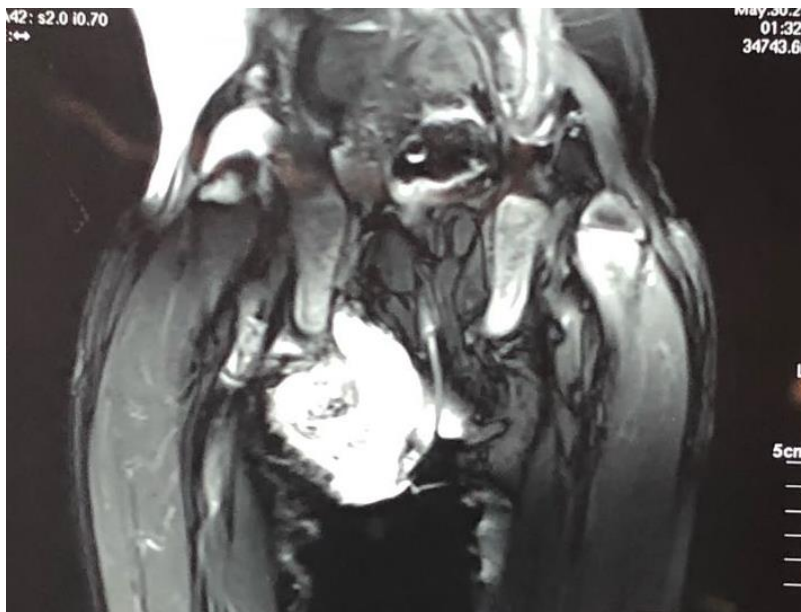


Image in Nephrology
Dr Kunwer Naveed Mukhtar
Department of Nephrology
Liaqat National Hospital
Karachi.
Email: naveedkunwer@yahoo.com.

MRI image of a 12 year old boy with Klipel Fiel Syndrome (conjugated fusion of the cervical vertebrae) presented to a general surgeon for thigh abscess and fracture. Patient was referred for high urea 189 mg/dl, creatinine 8.0mg/dl, calcium 10.5 mg/dl and i-PTH 2800 pmol/L.

What is the probable diagnosis?



Answer

Calciphylaxis (arrow) with tertiary hyperparathyroidism.
Patient was treated with cinacalcet and sevelamer hydrochloride along with low bicarbonate dialysis was done. The lesion resolved without surgical intervention.

Reference:

Ramon-Alberto Tamayo Isla and Mauro Cuba de la Cruz. Calciphylaxis in endstage renal disease prior to dialytic treatment. A case report and literature review. Int J Nephrol Renovasc Dis. 2015 2015;8:13-18